

Letter to the Editor

Experiences of ictal OP-MEG

Electroencephalography (EEG) is the gold standard investigation for epilepsy management. However, the ability of scalp EEG to detect and accurately source localise mesial temporal epileptiform activity remains controversial (Meckes-Ferber et al., 2004). Magnetoencephalography (MEG) is a non-invasive functional imaging modality similar to EEG. The localisation of MEG signals is less dependent on the anatomical model than EEG, and so can potentially be more accurate. Resecting the epileptogenic focus identified with MEG is a strong predictor of long-term seizure freedom post-surgery (Rampp et al., 2019). However, MEG has traditionally been limited by the cryogen required for the sensors, resulting in a large fixed system, meaning that patient movement is highly restricted and limiting compliance. Alternative sensors called optically pumped magnetometers (OPMs) can overcome some limitations of traditional MEG, allowing a system with movement tolerance more comparable to scalp EEG. OPM based MEG (OP-MEG) has been shown to increase the observed SNR of interictal epileptiform discharges (IEDs) in school-aged children by comparison with traditional MEG (Feys et al., 2022), and to successfully record interictal epileptiform activity from the mesial temporal lobe (Feys et al., 2025). While movement leads to interference in OP-MEG, the technique is considerably more motion tolerant than cryogenic MEG (Boto et al., 2018) and so may be more appropriate for such ictal recordings. Here we add to existing literature on ictal recordings in OP-MEG (Feys et al., 2023; Hillebrand et al., 2023) by demonstrating the ability to record seizures with varying degrees of movement from two epilepsy patients.

Ictal events were observed from two male patients. Ethical approval was given by the Essex Research Ethics Committee in the UK (REC Reference 18/EE/0220) and informed consent obtained. Demographics and clinical information can be found in Supplemental Table 1. Both patients had routine EEGs within normal limits, therefore necessitating prolonged recording. OPM data collection was performed within a Magnetically Shielded Room at UCL (Magnetic Shields Limited). 42 and 38 (for patients 1 and 2 respectively) zero-field OPMs (Gen-2.0 QZFM, QuSpin Inc.) were placed on the scalp in a bespoke 3D-printed scanner-cast, designed from the patient's MRI. Head position and rotation were recorded with 6 OptiTrack Flex 13 cameras (Natural Point Inc.). Each patient sat on a beanbag in the centre of the room with their head unconstrained for approximately 1 hour, monitored by a clinician seated in the room. During the ictal recordings, patient 1 was performing a verb generation task, while patient 2 (who has musicogenic epilepsy) was listening to music known to activate seizures.

Analysis was performed in SPM (<https://github.com/spm/spm>). Six 5th order Butterworth filters were applied bidirectionally to the OPM data: band-stop filters at 50 Hz, 100 Hz, 150 Hz and 120 Hz to remove line noise and interference from the OptiTrack cameras, a low-pass filter at 130 Hz and high-pass at 3 Hz. Homogeneous Field Correction (Tierney et al., 2021) was applied to minimise environmental interference. The ictal activity was localised using an LCMV Beamformer with the Nolte single shell forward model with the inner skull surface, segmented from the participant's MRI, and a 5 mm grid source space. For patient 2, this grid was extended to 5 cm outside of the scalp surface to include facial muscle locations as possible sources of the observed data, as the seizure involved facial automatism. For patient 1, the data covariance was estimated from a 10-min resting state recording to avoid biasing the sources to language areas, while the entire dataset recorded while the participant listened to music (10 min 36 s) was used for patient 2.

Patient 1 experienced a focal impaired awareness seizure (Fig. 1. A,B and Supplemental Fig. 1). During the seizure, there is an observed increase in oscillatory activity within the 13–30 Hz range, which localised to the left temporal lobe, consistent with the previous clinical assessment and MRI findings. Patient 2 indicated the beginning of the clinical seizure when experiencing an aura (time = 0 s in Fig. 1 C). During the seizure, the patient exhibited lip smacking and the urge to turn their head to the left, suggesting a right anterior quadrant seizure onset. Due to this head movement, large, low frequency signals are observed in the OPM data. Therefore, we have focussed on observed increased high frequency (60–130 Hz) power, which is less likely to be induced by movement. This localised bilaterally (right > left). The peak increase in power in the right hemisphere is adjacent to the inferior frontal gyrus (pars opercularis) (MNI coordinates: (55.5, 20.1, 0.2)). The maximum in the left hemisphere within the inner skull surface was found adjacent to the inferior frontal gyrus (pars triangularis) (MNI coordinates (–55.3, 19.9, –5.5)). The peaks in both hemispheres are adjacent to the respective superior temporal pole and gyrus.

Ictal OP-MEG from patient 1 shows clear activation localising to the expected region. With patient 2, we have examined observed increases in high frequency activity during this seizure. These localised close to the superior temporal gyri, often associated with musicogenic seizures (Stern, 2015), and the inferior frontal gyri, areas which have been associated with perceiving and enjoying music (Zatorre and Salimpoor, 2013). We cannot absolutely rule out that facial muscle artefacts or eye

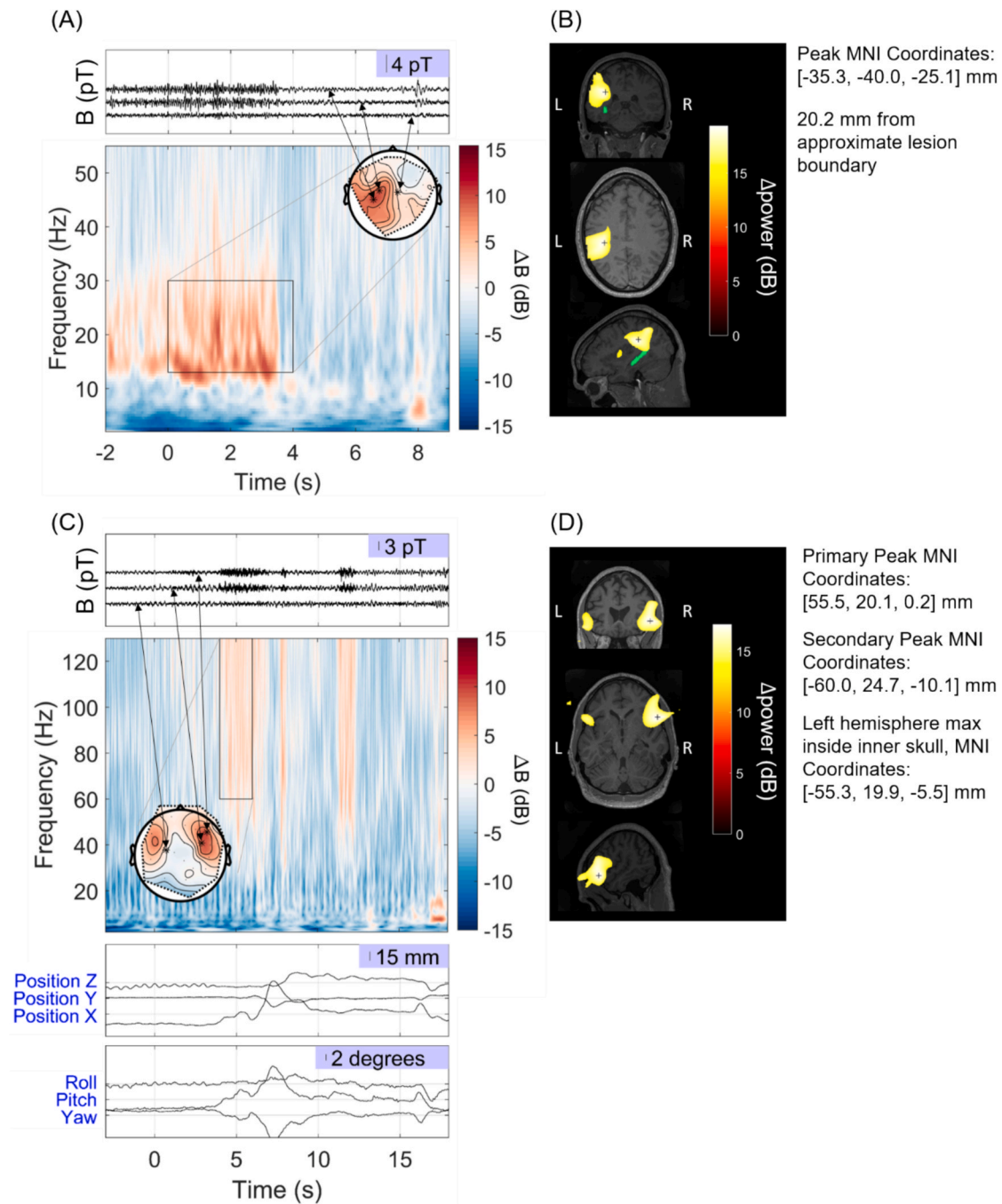
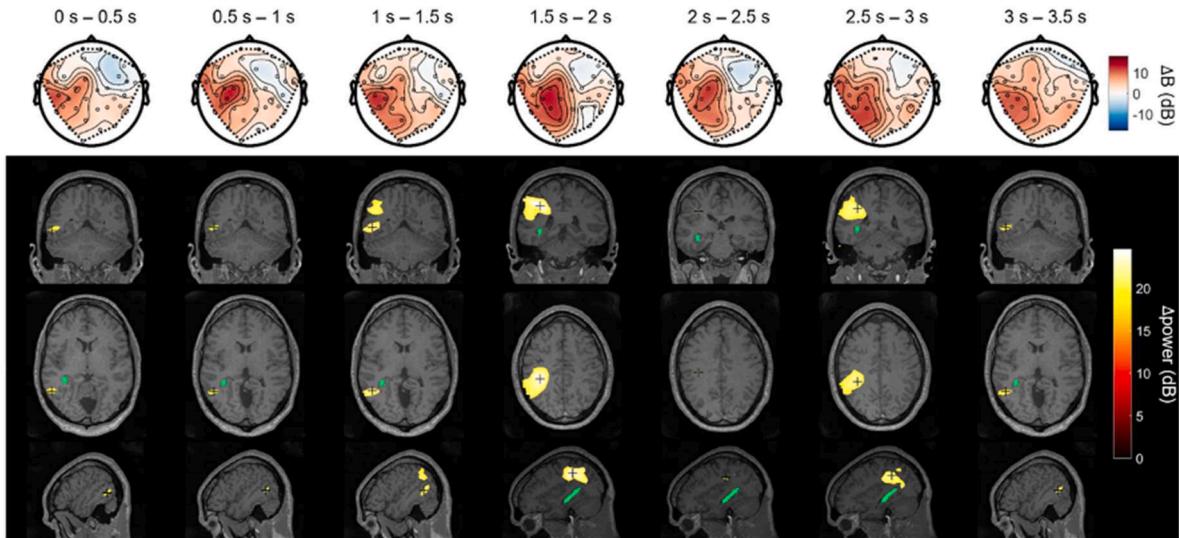


Fig. 1. A) Ictal activity observed from patient 1 at the sensor-level. The seizure onset was at 0 s. The time-frequency spectrum is shown averaged over all channels, baseline corrected by the average power in a rest recording, alongside the topography of the average change in power within the window of interest (0–4 s, 13–30 Hz) (showing only the OPM channels radial to the head) and the recorded magnetic field over time for 3 radial channels: the two with the highest and the one with the median average power change within that window. There is a visible increase in oscillatory activity between 0–4 s. There may also be an IED, as is often observed at the end of a seizure, at 8 s. B) LCMV beamformer localisation of this 13–30 Hz power increase, contrasting the 0–3 s window with the 4–7 s window. Thresholded at 80% of the maximum power change. The maximum power increase lies in the left temporal lobe and is marked by a black cross. The MRI abnormality is marked in green. C) Ictal activity observed with patient 2, shown at the sensor-level. Patient reported commencement of aura at 0 s. Equivalent of (A) but with the addition of participant head position and rotation. 4–6 s; 60–130 Hz was chosen as the window of interest based on the time-frequency spectrum. D) LCMV beamformer localisation of the increase in power in 60 Hz to 130 Hz frequency range between 4–6 s by comparison with -7 – -5 s, thresholded at 80% of the maximum power increase. The black cross shows the peak power location. (For interpretation of the references to colour in this figure legend, the reader is referred to the web version of this article.)

movements, could be the cause of these high frequency signals. However, despite including facial muscles as possible sources of activity, the peak of the activity was still observed within the brain. In future, this is likely to be less of a concern as there have recently been a number of developments in post-hoc software based interference correction for OP-MEG.

Anonymised OPM data will be made available upon request. Analysis code is available on GitHub (https://github.com/stephaniemellor/epilepsy_opm_ictal_analysis).

This work was partly funded by a Wellcome award which involves a collaboration agreement with QuSpin, a commercial entity selling optically pumped magnetometers (OPMs). None of the authors have



Supplemental Fig. 1. LCMV beamformer for different time windows during the event. As in Fig. 1B, the MRI abnormality is shown in green.

Patient No.	Years after epilepsy onset:		Findings from clinical MRI	Findings from clinical EEG telemetry	Ictal OP-MEG localisation
	OP-MEG	Clinical EEG			
1	19	19	Left temporal lobe grey matter heterotopia	Left temporal interictal; left neocortical ictal	Left parietal and temporal lobe, peak 20.2 mm from lesion boundary
2	13	9	Normal	Right temporal	Inferior frontal gyrus (R>L)

Supplemental Table 1. Patient demographics and clinical characteristics.

SM was funded by an Engineering and Physical Sciences Research Council (EPSRC) Healthcare Impact Partnership Grant (EP/V047264/1) and acknowledges support from the Federal Commission for Scholarships for Foreign Students for the Swiss Government Excellence Scholarship (ESKAS No. 2024.0251) for the academic year 2024–25. UV was funded by an MRC New Investigator Research grant (MR/T033150/1). GCO and DB are supported by a UKRI Frontier Research Grant (EP/X023060/1). TMT is funded by a fellowship from Epilepsy Research UK and Young Epilepsy (FY2101) and the National Brain Appeal Innovation Fund (NBA-IF 4). MS is supported by a Wellcome Technology development award (223736/Z/21/Z). This research was supported by the Discovery Research Platform for Naturalistic Neuroimaging funded by Wellcome (226793/Z/22/Z) and by the National Institute for Health and Care Research University College London Biomedical Research Centre. This work was supported by the Engineering and Physical Sciences Research Council through the UK Quantum Biomedical Sensing (Q-BIOMED) Research Hub.

potential conflicts of interest to be disclosed.

Name	Location	Contribution
Stephanie Mellor, PhD	Department of Imaging Neuroscience, UCL Queen Square Institute of Neurology, University College London, London WC1N 3AR, UK Spinal Cord Injury Center, Balgrist University Hospital, Zurich, Switzerland Translational Neuromodeling Unit (TNU), Institute for Biomedical Engineering, University of Zurich & ETH Zurich, Zurich, Switzerland	Study conceptualisation, methodology development, software development, formal analysis, data collection, writing – original draft, writing – review and editing
George C. O'Neill, PhD	Department of Neuroscience, Physiology and Pharmacology, University College London, London, UK	Study conceptualisation, methodology development, software development, data collection, writing – review and editing
Daniel Bush, DPhil	Department of Neuroscience, Physiology and Pharmacology, University College London, London, UK	Study conceptualisation, methodology development, software development, data collection, provision of resources, writing – review and editing
Arjun Ramaswamy, MRes	Department of Imaging Neuroscience, UCL Queen Square Institute of Neurology, University College London, London WC1N 3AR, UK Department of clinical and experimental epilepsy, UCL Queen Square Institute of Neurology, University College London, London WC1N 3AR, UK	Methodology development, software development, data collection, provision of resources, writing – review and editing
Ryan C. Timms, PhD	Department of Imaging Neuroscience, UCL Queen Square Institute of Neurology, University College London, London WC1N 3AR, UK	Methodology development, software development, data collection, investigation, writing – review and editing

(continued on next page)

(continued)

Name	Location	Contribution
David Doig, MD	Department of Neuroradiology, National Hospital for Neurology and Neurosurgery, Queen Square, London, WC1N 3BG, UK	Formal analysis, provision of resources, writing – review and editing
Tim M. Tierney, PhD	Department of Imaging Neuroscience, UCL Queen Square Institute of Neurology, University College London, London WC1N 3AR, UK	Methodology development, software development, writing – review and editing
Meaghan E. Spedden, PhD	Department of Imaging Neuroscience, UCL Queen Square Institute of Neurology, University College London, London WC1N 3AR, UK	Methodology development, software development, writing – review and editing
Matthew C. Walker, MD, PhD	Department of clinical and experimental epilepsy, UCL Queen Square Institute of Neurology, University College London, London WC1N 3AR, UK	Study conceptualisation, provision of resources, writing – review and editing
Gareth R. Barnes, PhD	Department of Imaging Neuroscience, UCL Queen Square Institute of Neurology, University College London, London WC1N 3AR, UK	Study conceptualisation, methodology development, software development, data collection, provision of resources, writing – review and editing
Umesh Vivekananda, MD, PhD	Department of clinical and experimental epilepsy, UCL Queen Square Institute of Neurology, University College London, London WC1N 3AR, UK	Study conceptualisation, formal analysis, data collection, provision of resources, writing – original draft, writing – review and editing

Declaration of Competing Interest

The authors declare that they have no known competing financial interests or personal relationships that could have appeared to influence the work reported in this paper.

References

- Boto, E., Holmes, N., Leggett, J., Roberts, G., Shah, V., Meyer, S.S., Muñoz, L.D., Mullinger, K.J., Tierney, T.M., Bestmann, S., Barnes, G.R., Bowtell, R., Brookes, M.J., 2018. Moving magnetoencephalography towards real-world applications with a wearable system. *Nature* 555, 657–661. <https://doi.org/10.1038/nature26147>.
- Feys, O., Corvilain, P., Aeby, A., Sculier, C., Holmes, N., Brookes, M., Goldman, S., Wens, V., De Tiège, X., 2022. On-scalp optically pumped magnetometers versus cryogenic magnetoencephalography for diagnostic evaluation of epilepsy in school-aged children. *Radiology* 304, 429–434. <https://doi.org/10.1148/radiol.212453>.
- Feys, O., Corvilain, P., Van Hecke, A., Sculier, C., Rikir, E., Legros, B., Gaspard, N., Leurquin-Sterk, G., Holmes, N., Brookes, M., Goldman, S., Wens, V., De Tiège, X., 2023. Recording of ictal epileptic activity using on-scalp magnetoencephalography. *Ann. Neurol.* 93, 419–421. <https://doi.org/10.1002/ana.26562>.
- Feys, O., Wens, V., Depondt, C., Rikir, E., Gaspard, N., Van Paesschen, W., Aeby, A., Bodart, O., Carrette, E., Holmes, N., Brookes, M., Ferez, M., Corvilain, P., De Tiège, X., 2025. On-scalp magnetoencephalography based on optically pumped magnetometers to investigate temporal lobe epilepsy. *Epilepsia* 66, e142–e151. <https://doi.org/10.1111/epi.18439>.
- Hillebrand, A., Holmes, N., Sijsma, N., O'Neill, G.C., Tierney, T.M., Liberton, N., Stam, A.H., van Klink, N., Stam, C.J., Bowtell, R., Brookes, M.J., Barnes, G.R., 2023. Non-invasive measurements of ictal and interictal epileptiform activity using optically pumped magnetometers. *Sci. Rep.* 13, 4623. <https://doi.org/10.1038/s41598-023-31111-y>.
- Meckes-Ferber, S., Roten, A., Kilpatrick, C., O'Brien, T.J., 2004. EEG dipole source localisation of interictal spikes acquired during routine clinical video-EEG monitoring. *Clin. Neurophysiol.* 115, 2738–2743. <https://doi.org/10.1016/j.clinph.2004.06.023>.
- Ramp, S., Stefan, H., Wu, X., Kaltenhäuser, M., Maess, B., Schmitt, F.C., Wolters, C.H., Hamer, H., Kasper, B.S., Schwab, S., Doerfler, A., Bli, I., Rö Sler, K., Buchfelder, M., 2019. Magnetoencephalography for epileptic focus localization in a series of 1000 cases. *Brain* 3059–3071. <https://doi.org/10.1093/brain/awz281>.
- Stern, J., 2015. Chapter 26 - Musicogenic epilepsy, in: Aminoff, M.J., Boller, F., Swaab, D.F. (Eds.), *Handbook of Clinical Neurology, The Human Auditory System*. Elsevier, pp. 469–477. Doi: 10.1016/B978-0-444-62630-1.00026-3.
- Tierney, T.M., Alexander, N., Mellor, S., Holmes, N., Seymour, R., O'Neill, G.C., Maguire, E.A., Barnes, G.R., 2021. Modelling optically pumped magnetometer interference in MEG as a spatially homogeneous magnetic field. *Neuroimage* 244, 118484. <https://doi.org/10.1016/j.neuroimage.2021.118484>.
- Zatorre, R.J., Salimpoor, V.N., 2013. From perception to pleasure: music and its neural substrates. *Proc. Natl. Acad. Sci.* 110, 10430–10437. <https://doi.org/10.1073/pnas.1301228110>.
- Stephanie Mellor^{a,b,c,*}, George C. O'Neill^d, Daniel Bush^d, Arjun Ramaswamy^{a,c}, Ryan C. Timms^a, David Doig^f, Tim M. Tierney^a, Meaghan E. Spedden^a, Matthew C. Walker^e, Gareth R. Barnes^a, Umesh Vivekananda^{e,**}
- ^a Department of Imaging Neuroscience, UCL Queen Square Institute of Neurology, University College London, London WC1N 3AR, UK
- ^b Spinal Cord Injury Center, Balgrist University Hospital, University of Zurich, Zurich, Switzerland
- ^c Translational Neuromodeling Unit (TNU), Institute for Biomedical Engineering, University of Zurich & ETH Zurich, Zürich, Switzerland
- ^d Department of Neuroscience, Physiology and Pharmacology, University College London, London, UK
- ^e Research Department of Epilepsy, UCL Queen Square Institute of Neurology, University College London, London WC1N 3AR, UK
- ^f Department of Neuroradiology, National Hospital for Neurology and Neurosurgery, Queen Square, London WC1N 3BG, UK

* Corresponding author at: Department of Imaging Neuroscience, UCL Queen Square Institute of Neurology, University College London, London WC1N 3AR, UK.

** Corresponding author.

E-mail addresses: stephanie.mellor.17@ucl.ac.uk (S. Mellor), u.vivekananda@ucl.ac.uk (U. Vivekananda).